

CASE REPORT

OPEN ACCES

Cite as:

Morales-Coloma M. A case report of blastic plasmacytoid dendritic cell neoplasm in a pediatric patient: an unusual age of presentation. 2023;2(1).

Received:

25-10-2023

Approved:

25-11-2023

Author's contributions:

MMC participated in the conception of the article, discussion of evidence, writing and approval of the final version.

Financing:

None.

Conflicts of interest:

The authors declare that they have no conflict of interest.

Correspondence:

Melissa Morales-Coloma
E-mail: melissamorales.col@gmail.com

A case report of blastic plasmacytoid dendritic cell neoplasm in a pediatric patient: an unusual age of presentation

Reporte de un caso de neoplasia blástica de células dendríticas plasmocitoides en un paciente pediátrico: una edad inusual de presentación

Melissa Morales-Coloma¹ 

¹ Pediatric Hematology and Bone Marrow Transplantation Unit, Instituto Nacional del niño San Borja, Lima, Peru.

^a MD

ABSTRACT

Blastic Plasmacytoid Dendritic Cell Neoplasm (BPDCN) is a rare type of cancer with aggressive behavior, most commonly found in adults. However, it is very uncommon in children, and documented evidence is limited. Herein, we present the case of a 6-year-old patient diagnosed and treated at the National Institute of Health for Children in Lima.

Keywords

blastic plasmacytoid dendritic cell neoplasm, cancer, child (source: MeSH-NLM).

RESUMEN

La neoplasia blástica de células dendríticas plasmocitoides (BPDCN) es un tipo raro de neoplasia con comportamiento agresivo, que se encuentra con mayor frecuencia en adultos. Sin embargo, es muy poco común en niños y la evidencia documentada es limitada. Se presenta el caso de un paciente de 6 años diagnosticado y atendido en el Instituto Nacional de Salud del Niño de Lima.

Palabras clave

Neoplasia blástica de células dendríticas plasmocitoides; neoplasia ; niño (fuente: DeCS-BIREME).

INTRODUCTION

Since the 4th edition of the WHO classification in 2017, BPDCN has been categorized separately within Myeloid Leukemias ⁽¹⁾. The latest edition, updated in 2022, emphasized the immunophenotypic diagnostic criteria as a key change ⁽²⁾. This rare neoplasm shows no ethnic predilection and presents with a male-to-female ratio of 3.3/1. While the mean age at onset is 64 years, BPDCN can occur at any age.

This neoplasia typically infiltrates the skin in 64% to 100% of cases, the bone marrow (BM) in 60% to 90%, and lymph nodes in 40% to 50% of cases. In 20% of cases, bone marrow involvement is observed without skin involvement ⁽³⁾. However, relapse in both the skin and central nervous system (CNS) is almost inevitable.

To date, due to its rarity, there are limited research collaborative groups dedicated to studying BPDCN with the aim of standardizing the treatment approach and devising the management of relapses/progression in both children and adults.

CASE REPORT

A 6-year-old female patient, without significant medical history, was referred due to a 2-week history of bone pain, asthenia, distal paresthesias in all four limbs, and fever. The complete blood count revealed moderate anemia (hemoglobin: 6.8 g/dL), leukocytosis (leukocytes: 5740 $10^3/uL$, neutrophils: 3560 $10^3/uL$), 10% lymphoid-type

blasts, a low platelet count of 100 $10^3/uL$, elevated lactate dehydrogenase (LDH: 650 UI/L), and increased C-reactive protein (CRP: 21 mg/dL). Physical examination highlighted marked pallor, hepatosplenomegaly (both enlarged by 5 cm), and multiple cervical, axillary, and inguinal lymphadenopathies ranging from 2 to 3 cm in diameter. A neurological evaluation revealed no focalization or meningeal signs and preserved tendon reflexes. However, the patient reported pain (VAS 6/10) and paresthesias in all four limbs.

The myelogram, bone marrow biopsy (BM), and BM flow cytometry confirmed the diagnosis of BPDCN, revealing the positive expression of CD4, CD56, CD123, CD45, HLA-DR, CD7, CD33, CD38, CD36, and NG2, primarily observed in 66.86% of blasts. Additionally, CD117 was expressed in 25% of blasts (Figure 1). Conversely, markers such as CD34, cy MPO, cy CD79a, cy CD3, CD16, CD11b, CD13, CD10, CD15, CD64, CD14, and CD2 were negative. The results from cytogenetics and the molecular panel did not contribute to the diagnosis.

Upon BPDCN diagnosis, the medical board opted for an acute lymphoblastic leukemia-like (ALL-like) treatment. The induction phase involved administering daunorubicin at 30 mg/m², vincristine at 1.5 mg/m² weekly for four weeks, and Ecoli asparaginase at 10,000 UI/m² for eight weeks. During this induction treatment, the patient developed severe headaches (VAS 8-9/10) and continued to experience initial symptoms, including paresthesias and distal pain in all four limbs. This raised suspicion of central nervous system (CNS) infiltration. A lumbar puncture (LP) was performed, revealing a positive flow cytometric

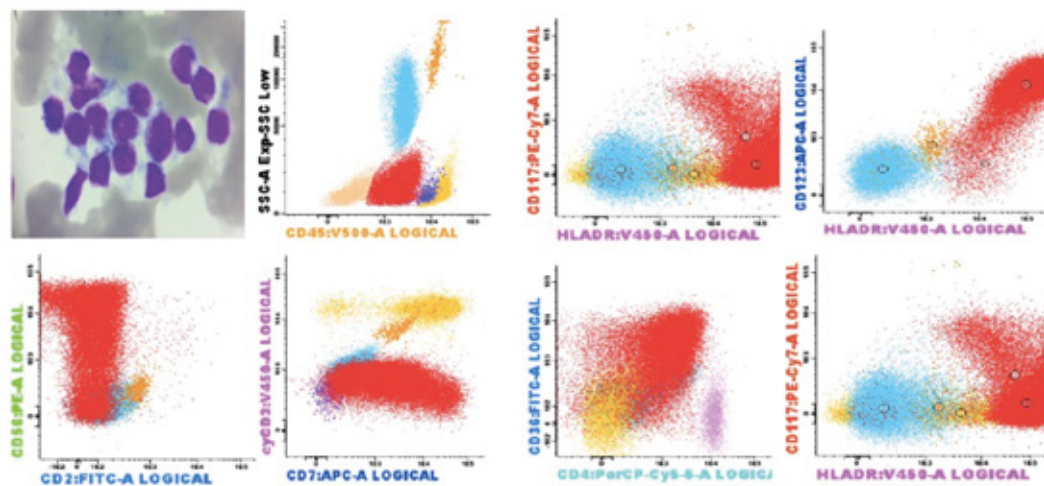


Figure 1. The bone marrow flow cytometry showing positivity for CD4, CD56, CD123, CD45, HLA-DR, CD7, CD33, CD38, CD36, NG2, and CD117 markers.

immunophenotyping (FCI) of cerebrospinal fluid (CSF). Brain tomography and magnetic resonance imaging (MRI) scans showed no abnormalities. To address CNS infiltration, the patient underwent serial triple intrathecal therapies (TIT), receiving two treatments per week. The FCI-CSF became negative after the third LP, and a total of seven TIT sessions were administered.

During the induction phase, the patient experienced febrile neutropenia, originating from the oral cavity, and vulvovaginal candidiasis. Post-induction MRD (minimal residual disease) testing yielded negative results. Subsequently, her treatment regimen included Cytarabine at 1.5 mg/m² bid for 4 days, along with Mitoxantrone at 10 mg/m² qd for 2 days. However, during this phase, she developed oropharyngeal candidiasis. Following the second chemotherapy course, both BM and CSF MRD results were negative. The possibility of allogeneic *haematopoietic stem cell transplantation* (Allo-HSCT) was considered, but the only 8-year-old brother was found to be only haplocompatible.

A control was performed before initiating the next chemotherapy regimen, and the BM was found to be in CR; however, FCI-CSF remained positive. Subsequently, the patient experienced a CNS relapse, and received an individualized scheme (weekly Vincristine 1,5 mg/m² + Adriamycin 30 mg/m²) along with serial TIT, completing 6 TIT sessions. CSF became negative on the third LP, and continued to receive cyclophosphamide and low-dose cytarabine while receiving serial TIT. Then, cellular atypia was detected during the tenth TIT session, coinciding with the onset of neurological symptoms and negative imaging results. CSF flow cytometry was performed with a positive result defined as more than 10 events with the diagnostic phenotype and a cellularity of ≥ 0.01 cells/uL.

To evaluate CR of extramedullary disease before considering haploidentical HSCT, the decision was made to begin whole-brain radiotherapy. The patient completed 12 sessions of 12Gy, during which she developed severe grade III-IV mucositis. Following hematological recovery, a high dose of Methotrexate (5 g/m²) was administered, resulting in an MRD control of 1.2%. Unfortunately, subsequent severe neutropenia led to her admission to the ICU due to septic shock and neutropenic enteritis. Her recovery was slow and complicated, ultimately leading to the decision for palliative care. She died one month later.

DISCUSSION

Published data on BPDCN are limited, particularly in children. A recent comprehensive review by Cuglievan *et al.* covered various aspects of the disease, encompassing

diagnosis, treatment, and emerging therapies. It was highlighted that pediatric BPDCN, while clinically less aggressive, frequently exhibits a higher degree of dissemination compared to adult cases⁽⁴⁾.

An important report on pediatric BPDCN by Jegalian *et al.* in 2010 evaluated 25 cases of patients under 18 years of age. Notably, the 5-year overall survival (OS) rate was 36% for the patients, with only a third of them undergoing HSCT. Additionally it was pointed that cases without skin infiltration at the outset had a more favorable clinical course, in contrast to adults, where this difference did not significantly impact the prognostic evaluation⁽⁵⁾.

A more recent study conducted by Dueñas *et al.*, reported 24 Peruvian patients from 2005 to 2014, with ages ranging from 8 to 82 years. They found that patients were younger than expected compared with other countries, being 24% (9 cases) of all cases younger than 18 years old. Likewise, there was a female predominance, CNS infiltration was present in 26% (10 cases), and most patients (42%) received ALL-like treatment of all cases⁽⁶⁾.

The recommended chemotherapy regimen was similar to that used for ALL⁽⁴⁾. In 2017, Kym *et al.* reported more favorable outcomes in pediatric patients compared to adults. Pediatric patients were more likely to achieve complete remission (CR) at a rate of 86% versus 52% in adults ($p < 0.01$). When utilizing ALL protocols, pediatric patients showed higher remission rates (93%) in contrast to ALM and lymphoma protocols (77% and 47% respectively). Additionally, pediatric patients demonstrated a lower likelihood of disease recurrence compared to adults, with rates of 27% versus 57% ($p < 0.01$) respectively⁽⁷⁾.

Reported rates of CNS involvement in BPDCN range widely from 20% to 60%; however, the precise incidence remains unknown. Within the pediatric group, approximately 60% exhibit CNS disease, with a remarkable majority being asymptomatic and diagnosed solely through CSF cytology⁽⁴⁾. Notably, in contrast to the adult population, a high-risk ALL-like regimen has shown considerable success in curing the majority of cases within the pediatric group⁽⁴⁾. Additionally, the response to prednisone, coupled with high doses of methotrexate, has demonstrated its effectiveness as a protective factor against extramedullary and medullary relapses, respectively⁽⁵⁾.

Regarding allo-HSCT, the recommendation stands to introduce it in the second CR, for those failing to achieve CR, or for cases where disease response is slow to upfront ALL-like therapy. This approach stems from the fact that pediatric patients with BPDCN generally exhibit a more favorable prognosis compared to adults. Therefore, allo-HSCT after the first CR is advised primarily for pediatric

patients displaying high-risk factors⁽⁴⁾. A systematic review highlighted that pediatric patients undergoing allogeneic HSCT had a significantly higher median survival of 37.8 months compared to adults (21.1 months; $p \leq 0.01$) with BPDCN⁽⁷⁾. However, despite these promising outcomes, a noteworthy percentage of patients experienced relapses in both the bone BM and CNS post allo-HSCT⁽⁴⁾.

In the presented clinical case, significant challenges arose in treating the extramedullary infiltration of this little-known neoplasm. Despite adapting the treatment protocol to include serial TIT and extending intravenous chemotherapy due to the risk of medullary relapse, the infiltration persisted. Consequently, the decision was made to employ whole-brain radiotherapy as a final measure to achieve extramedullary remission and facilitate the continuation of an adjusted regimen, akin to that used for ALL.

Promising advancements in the treatment of this rare condition are underway. SL401, the initial therapy targeting the CD123 receptor, showed promising results in phase 2 trials among adults, achieving a favorable response rate of 90% in cases and demonstrating good tolerability in children. Nevertheless, additional studies are necessary to validate and confirm its effectiveness^(8,9).

In conclusion, this review emphasizes the recommendation of High-Risk ALL chemotherapy, considering prednisone response as a prognostic factor and ensuring CNS prophylaxis. The clinical presentation between pediatric and adult groups is similar. Notably, in the pediatric group, the absence of skin infiltration at onset positively impacts overall survival. Managing CNS involvement poses challenges; no standardized treatment was identified during this review. However, our approach involved radiotherapy, showing an initial favorable response. Further comprehensive studies encompassing morphology, cytogenetics, and immunohistochemistry are imperative to outline age-based differences. These investigations are crucial in unraveling potential targeted therapies.

REFERENCES

1. Arber DA, Orazi A, Hasserjian R, Thiele J, Borowitz MJ, Le Beau MM, et al. The 2016 revision to the World Health Organization classification of myeloid neoplasms and acute leukemia. *Blood*. 2016;127(20):2391-405. doi: 10.1182/blood-2016-03-643544.
2. Khoury JD, Solary E, Abela O, Akkari Y, Alaggio R, Apperley JF, et al. The 5th edition of the World Health Organization Classification of Haematolymphoid Tumours: Myeloid and Histiocytic/Dendritic Neoplasms. *Leukemia*. 2022;36(7):1703-1719. doi: 10.1038/s41375-022-01613-1.
3. Sapienza MR, Pileri A, Derenzini E, Melle F, Motta G, Fiori S, et al. Blastic Plasmacytoid Dendritic Cell Neoplasm: State of the Art and Prospects. *Cancers (Basel)*. 2019;11(5):595. doi: 10.3390/cancers11050595.
4. Cuglievan B, Connors J, He J, Khazal S, Yedururi S, Dai J, et al. Blastic plasmacytoid dendritic cell neoplasm: a comprehensive review in pediatrics, adolescents, and young adults (AYA) and an update of novel therapies. *Leukemia*. 2023;37(9):1767-1778. doi: 10.1038/s41375-023-01968-z.
5. Jegalian AG, Buxbaum NP, Facchetti F, Raffeld M, Pittaluga S, Wayne AS, et al. Blastic plasmacytoid dendritic cell neoplasm in children: diagnostic features and clinical implications. *Haematologica*. 2010;95(11):1873-9. doi: 10.3324/haematol.2010.026179.
6. Dueñas D, Cervantes E, Enriquez DJ, Flores C, Barrionuevo C, Alcarraz C, et al. Clinical Characteristics, Immunophenotype and Outcomes of Blastic Plasmacytoid Dendritic Cell Neoplasms in a Peruvian Cohort. *Blood*. 2020;136 (Supplement 1):42-3. doi: 10.1182/blood-2020-143212.
7. Kim MJM, Nasr A, Kabir B, De Nanassy J, Tang K, Menzies-Toman D, et al. Pediatric Blastic Plasmacytoid Dendritic Cell Neoplasm: A Systematic Literature Review. *J Pediatr Hematol Oncol*. 2017;39(7):528-537. doi: 10.1097/MPH.0000000000000964.
8. Cuglievan B, Connors J, He J, Khazal S, Yedururi S, Dai J, et al. Blastic plasmacytoid dendritic cell neoplasm: a comprehensive review in pediatrics, adolescents, and young adults (AYA) and an update of novel therapies. *Leukemia*. 2023;37(9):1767-1778. doi: 10.1038/s41375-023-01968-z.
9. Wilson NR, Konopleva M, Khoury JD, Pemmaraju N. Novel Therapeutic Approaches in Blastic Plasmacytoid Dendritic Cell Neoplasm (BPDCN): Era of Targeted Therapy. *Clin Lymphoma Myeloma Leuk*. 2021;21(11):734-740. doi: 10.1016/j.clml.2021.05.018.

